

MedED Year 5 Pathology Mock – 2022

Total /55

Microbiology

1. A 50 year-old gentleman presents to the GP following surgery 10 days ago. The wound is tender, erythematous and you notice pus discharging. Microscopy and Gram stain of a wound swab demonstrates purple cocci in clusters, which are catalase positive and coagulase negative. What is the most likely organism?
 - a. Staphylococcus aureus
 - b. Staphylococcus epidermidis
 - c. Staphylococcus saprophyticus
 - d. Streptococcus pyogenes
 - e. Streptococcus pneumoniae

2. A 75 year-old lady presents to ED with shortness of breath, productive cough and fever. On examination, her respiratory rate is 34 and blood pressure is 94/59. Crackles are heard at the left lung base. She is orientated. Blood results show a urea of 9.5. How would you manage this patient?
 - a. Discharge with PO amoxicillin
 - b. Admit for PO amoxicillin and PO clarithromycin
 - c. Admit for IV amoxicillin and IV clarithromycin
 - d. Admit for IV co-amoxiclav and IV clarithromycin
 - e. Admit for IV co-amoxiclav, IV clarithromycin and IV gentamycin

3. A 25 year-old man develops fever, abdominal cramps and foul-smelling bloody diarrhoea. His girlfriend has similar symptoms. They both attended a barbeque 2 days ago. What is the most likely causative organism?
 - a. Staphylococcus aureus
 - b. Vibrio cholera
 - c. Salmonella typhi
 - d. Campylobacter jejuni
 - e. Entamoeba histolytica

4. A 40 year-old man returns from travelling in India. He develops a fever, headaches, myalgia and reports constipation. On examination, small pink spots are noted on his chest. A diagnosis of typhoid fever is suspected. Which antibiotic treatment is most appropriate?
 - a. PO metronidazole
 - b. IV gentamycin and PO ciprofloxacin
 - c. IV ceftriaxone then PO azithromycin

- d. IV vancomycin
 - e. PO doxycycline then PO clarithromycin
5. A 19 year-old student presents to ED with a fever, headache, photophobia and neck stiffness. You are concerned about meningitis and perform a lumbar puncture. This shows clear CSF. On analysis, the glucose is normal, protein is normal and white cells are raised (mononuclear cells). What is the most likely causative organism?
- a. Neisseria meningitidis
 - b. Listeria monocytogenes
 - c. Cryptococcus neoformans
 - d. Rotavirus
 - e. Coxsackie virus
6. A medical student undergoes blood-borne virus screening before starting clinical placements. They test positive for HBsAg and Anti-HBc; negative for IgM anti-HBc and anti-HBs. What is their HBV infection status?
7. A vegetarian returns from holiday in Morocco and presents jaundiced. They complain about the food options available and explain that they ended up eating a lot of salad. What is the most likely diagnosis?
8. Name the mechanism which drives rapid genetic change in influenza virus.
9. A patient with dark skin presents with dandruff and patches of depigmentation which appeared quite suddenly; usually their hair is impeccable. What is the most likely diagnosis?
10. A patient with diabetes who is non-compliant with their glycaemic control agents presents with pain and redness around the eye. As they wait in A&E majors they start to discharge black pus from their mouth and nose. What is the most likely diagnosis?

Chemical Pathology

1. Both mother and grandmother had medullary thyroid carcinoma and have tested positive for MEN2. What [biomarker/protein] would be raised in the blood to confirm medullary thyroid cancer?
 - a. Calcitriol
 - b. Calcitonin
 - c. Thyroglobulin
 - d. Thyroxine
 - e. TPO
2. What blood marker is used to check for recurrence of papillary thyroid cancer post resection?
 - a. Calcitriol
 - b. Calcitonin
 - c. Thyroglobulin
 - d. Thyroxine
 - e. TPO
3. A patient presents with new-onset type 2 diabetes, an enlarged jaw and forehead and carpal-tunnel syndrome. Which investigation would be most useful to diagnose the likely cause?
 - a. Oral glucose tolerance test
 - b. IGF-1
 - c. Serum prolactin
 - d. Short synACTHen test
 - e. Pituitary MRI
4. A 55 year old patient presents with low blood pressure, increased pigmentation of skin creases, low glucose, low sodium and high potassium

What is the best investigation to order to confirm the likely diagnosis?

- a. Serum cortisol
- b. 24 hour urinary cortisol
- c. Short SynACTHen test
- d. Insulin tolerance test
- e. Plasma renin - aldosterone ratio

5. A woman has diarrhoea, sweating, fever and palpitations for the last week. Bloods show low TSH and high thyroxine. She does not have good uptake on technetium scan. What is the likely diagnosis?
- a. Hashimoto's
 - b. Grave's
 - c. Thyroid adenoma
 - d. De Quervain's
 - e. Toxic multinodular goitre
6. What antibodies are tested for in the laboratory diagnosis of Hashimoto's thyroiditis?
- a. anti TSH and anti TPO
 - b. anti TRH and anti TSH
 - c. anti TPO and anti TG
 - d. anti TG and anti TSH
 - e. anti TRH and anti TPO

Immunology

1. A 34 year old woman presents with abdominal discomfort and duodenal biopsy demonstrates intraepithelial lymphocyte infiltration, villous atrophy and crypt hyperplasia. Which is the most likely HLA association?
 - a. DR2
 - b. DR3
 - c. DR4
 - d. DQ2
 - e. B27
2. A 2 year old boy presents with pneumocystis jirovercii and has previous history of CMV hepatitis. There is failure to make germinal centres. There are low IgG, IgA and IgE and high IgM. What is the pathophysiology?
 - a. Defect in tyrosine kinase
 - b. 2q11 microdeletion
 - c. Defect in CD18
 - d. Microtubule dysfunction
 - e. Defective CD40L
3. A 5 year old boy presents with hepatomegaly, lymphadenopathy, previous infections with Listeria and a S. aureus abscess. Dihydrorhodamine flow cytometry does not result in rhodamine. What is the best treatment?
 - a. Interferon gamma
 - b. Antibiotics
 - c. Haematopoietic Stem cell transplant
 - d. Immunisation
 - e. Antifungals
4. A 40 year old woman presents complaining of her skin shining, edematous fingers and fatigue which are difficult to move. Her face is not expressive and she has microstomia. Her CT chest is below. Which is the most likely antibody?
 - a. Anticentromere
 - b. Anti-Scl-70
 - c. Antimitochondrial
 - d. Anti-dsDNA
 - e. Anti-GBM
5. A 37 year old woman presents with fatigue, malar flash worsened by sunlight, symmetrical arthritis of the PIP joints. On examinations she also has ulcers in her mouth. What type of hypersensitive reaction is this?

- a. Type I
 - b. Type II
 - c. Type III
 - d. Type IV
 - e. Graft vs Host
6. A 35-year-old man develops diarrhoea with fever and malaise 24 hours after eating a take-away meal. Stool cultures reveal the source of the infection is *Salmonella* spp. Which antibody is responsible for protecting against gastrointestinal infections?
- a. IgA
 - b. IgD
 - c. IgE
 - d. IgG
 - e. IgM
7. Which of the following is a subunit vaccine?
- a. Diphtheria
 - b. Pneumococcus
 - c. MMR
 - d. Yellow Fever
 - e. HPV – capsid
8. Which of the following is a conjugate vaccine?
- a. Diphtheria
 - b. Pneumococcus – encapsulated bacteria
 - c. MMR
 - d. Yellow Fever
 - e. HPV
9. Which of the following is not safe in patients with HIV?
- a. Diphtheria
 - b. Pneumococcus
 - c. MMR
 - d. Yellow Fever
 - e. HPV
10. Which of the following is a live attenuated vaccine that is safe in patients with HIV?
- a. Diphtheria
 - b. Pneumococcus

- c. MMR
- d. Yellow Fever
- e. HPV

11. Ipilimumab is a licensed therapy in the treatment of metastatic melanoma, but which receptor does it bind to?

- a. CD3
- b. CTLA4
- c. IL2
- d. RANKL
- e. TNF-alpha

12. Which MHC is most important when matching donors

- a. A
- b. B
- c. C
- d. DQ
- e. DR

13. Which type of rejection can be treated with plasmapheresis?

- a. Acute antibody mediated
- b. Acute cell mediated
- c. Chronic
- d. Graft versus Host Disease
- e. Hyperacute

14. Which type of rejection leads to fibrosis?

- a. Acute antibody mediated
- b. Acute cell mediated
- c. Chronic
- d. Graft versus Host Disease
- e. Hyperacute

Haematology

1. A previously healthy 40-year-old man presented to A&E with confusion, and difficulty speaking, which developed an hour before presentation. He had had a fever, cough, headache, and bleeding from the gums for 10 days. On examination, the patient's blood pressure was 160/100 mm Hg, pulse 94 beats/min, respiratory rate 14 breaths/min, and temperature 38.0 °C. His kidney function had deteriorated, and he had become oliguric. The peripheral blood film showed thrombocytopenia and schistocytes. What is the most likely diagnosis?
 - a. MAHA
 - b. DIC
 - c. TTP
 - d. HUS
 - e. Acute Intermittent Porphyria
2. A lady comes in with dizziness and shortness of breath which has increased in frequency over the last four months. This is associated with symptoms of anergia and anhedonia. She mentions that she has become a vegetarian in the last two years. Her blood are shown: MCV 105, Hb 90, TSH 7.0, ALT 45, AST 70, GGT NAD.

Which of the following is least likely to be a cause for the patient's symptoms?

- a. Alcohol
 - b. Hashimoto's Disease
 - c. Sideroblastic Anemia
 - d. B12 deficiency
 - e. Pregnancy
3. Which of the following would be consistent with iron deficiency anemia?
 - a. ↓iron, ↓ferritin, ↑transferrin, ↑TIBC
 - b. ↓iron, ↓ferritin, ↓transferrin, ↓TIBC
 - c. ↑iron, ↑ferritin, ↑transferrin, ↑TIBC
 - d. ↓iron, ↓ferritin, ↓transferrin, ↓TIBC
 - e. ↓iron, ↑ferritin, ↑transferrin, ↑TIBC
 4. Which of the following is least likely to be a cause of schistocytes in the peripheral blood film?
 - a. MAHA
 - b. HUS
 - c. TTP
 - d. DIC
 - e. VWD

5. A 75-year-old man is an inpatient on a gastroenterology ward after being admitted for an upper gastrointestinal bleed secondary to esophageal varices. He has become short of breath over the last 20 minutes. HR 90 beats /min, RR 32 /min, BP 185/56 mmHg, O2 Saturations 92% on air, temperature 39.7°C. On examination he has bilateral inspiratory crepitations. Heart sounds are normal and JVP is 5cm above the sternal angle. No rash or swelling is noted. The patient had completed a blood transfusion of 1 unit of blood 2 hours ago.

What is the most likely transfusion reaction?

- a. Acute Haemolysis
 - b. Transfusion related acute lung injury
 - c. Transfusion associated circulatory overload
 - d. Non – haemolytic transfusion reaction
 - e. Anaphylaxis
6. Which one of the following would you expect to be raised during Pregnancy?
- a. Protein S
 - b. Platelets
 - c. Mean Cell Volume
 - d. Hemoglobin
 - e. Hematocrit
7. Which are the following is not a laboratory feature of hemolytic anemia?
- a. Raised reticulocytes
 - b. High LDH
 - c. High Haptoglobin
 - d. Anemia
 - e. High Potassium
8. A 60 year old man presents with back pain and is found to have a lytic lesion in the L2 vertebra. Blood tests are requested and show:
- Haemoglobin 130g/l (130-170)
 - Platelet count 250 (150-400)
 - White cell count 8.3 (4-11)
 - Creatinine 95 (60-100)
 - Calcium 2.60 (2.20-2.60)
 - Immunoglobulins and protein electrophoresis:
 - *IgG kappa paraprotein 22g/l detected on protein electrophoresis*

What is the most likely diagnosis?

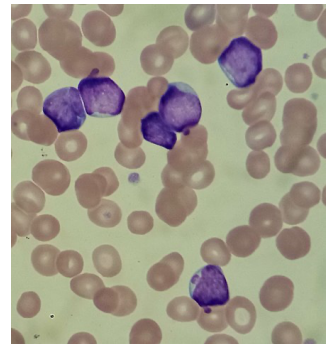
- a. Monoclonal gammopathy of unknown significance (MGUS)
- b. Smouldering myeloma
- c. Multiple myeloma
- d. AL amyloidosis
- e. Adenocarcinoma of the prostate

9. A 50 year old lady presents to A&E with chest pains. Her blood tests show:

- Haemoglobin 119/l (130-170)
- Platelet count 77 (150-400)
- White cell count 19.5 (4-11)
- Neutrophils 1.0 (1.5-7)
- Lymphocytes 0.2 (1-4)
- Blasts 18.1

Blood film is shown on the right.

The blood is sent for urgent immunophenotyping which shows 91% of total nucleated cells: positive for CD10 CD19 CD22 CD34 CD66c HLADR TdT CD79a



What is the diagnosis?

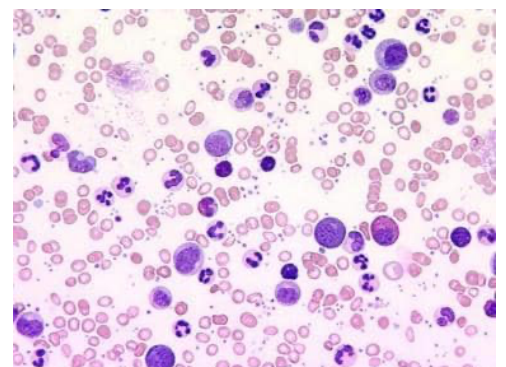
- a. Acute myeloid leukaemia
- b. Hairy cell leukaemia
- c. Acute lymphoblastic leukaemia
- d. Chronic myeloid leukaemia
- e. Chronic lymphocytic leukaemia

10. A 58 year old man presents to his GP with worsening left upper quadrant pain. He is found to have a palpable splenomegaly and blood tests are organised. Results are shown below:

- Haemoglobin 135/l (130-170)
- Platelet count 502 (150-400)
- White cell count 132 (4-11)
- *Automated differential not possible*

Fluorescence in-situ hybridisation (FISH) is performed and demonstrates the presence of t(9;22)

The blood film is shown



What is the diagnosis?

- a. Chronic lymphocytic leukaemia
- b. Chronic myeloid leukaemia
- c. Myelofibrosis
- d. Myelodysplastic syndrome
- e. Essential thrombocytosis

11. 21 year old lady presents to A&E with chest pain and palpitations. A CT Pulmonary Angiogram is performed which shows abnormal lymphadenopathy in the mediastinum and hilar regions. Blood tests show an elevated white blood cell count (16.1 [4-11]) due to a marked eosinophilia (6.4[0.1-0.5]) and are otherwise normal. A biopsy is undertaken which shows:

The nodules are composed of small lymphocytes with admixed macrophages and eosinophils. Scattered against this background are large, atypical lymphoid cells which possess prominent nucleoli. These large cells are Reed-Sternberg cells and include mononuclear, binuclear and lacunar forms.

What is the diagnosis?

- a. Follicular lymphoma
- b. Chronic eosinophilic leukaemia
- c. Hodgkin's Lymphoma
- d. Small lymphocytic lymphoma
- e. Chronic myeloid leukaemia

12. A 78 year old man presents to hospital with sepsis due to pneumonia. On admission he is noted to have an abnormal full blood count and on further questioning he has received several courses of antibiotics in the community.

- Haemoglobin 85/l (130-170)
- Platelet count 34 (150-400)
- White cell count 1.1 (4-11)
- Neutrophils 0.4 (1.5-7)
- Lymphocytes 0.7 (1-4)
- Eosinophils 0.0 (0.1-0.5)
- Basophils 0.0 (0-0.1)
- Monocytes 0.0 (0.1-1.0)

Bone marrow examination is performed which shows:

The bone marrow is normocellular for age. Dysplastic features noted in megakaryocytes, erythroid cell line and granulocytes. Myeloid blasts are present and account for 8% of total nucleated cells.

What is the most likely diagnosis?

- a. Acute myeloid leukaemia
- b. Acute lymphoblastic leukaemia
- c. Myelodysplastic syndrome
- d. Myelofibrosis
- e. Aplastic anaemia

13. What is the mode of inheritance of G6PD deficiency?

14. Which enzyme deficiency is associated with thrombotic thrombocytopenic purpura?

15. Which blood product is more likely to be contaminated by bacteria?

Histopathology

1. Which of the following would confirm lymphocytic duodenitis?

- a. Villous atrophy
- b. Intraepithelial lymphocytes > 20/100
- c. Crypt hyperplasia
- d. Low serum B12
- e. Thickened basement membrane

2. What is likely to be seen on biopsy of a child with Hirschsprung's disease?

- a. Absent nerve fibres
- b. Increased chromatin and number of nuclei
- c. Normal biopsy
- d. Absent myenteric ganglia
- e. Increase mitotic figures with evidence of basement membrane disruption

3. 65 year old gentleman presents to his GP after complaining of a change of bowel habit and some fresh blood in the stools. He goes on to have a colonoscopy which shows some polyps. Which of the following indicates a higher risk of malignant transformation?

- a. Higher villous component
- b. Higher tubular component
- c. Polyp size of 2cm
- d. Solitary polyp on background of normal mucosa
- e. Degree of anaemia

4. What is the most common type of renal stone?
 - a. Uric acid stone
 - b. Magnesium ammonium phosphate (struvite)
 - c. Calcium pigment stones
 - d. Calcium oxalate
 - e. Sodium oxalate

5. What is the most common type of malignant renal cell carcinoma?
 - a. Papillary cell
 - b. Transitional cell
 - c. Clear cell
 - d. Chromophobe cell
 - e. Squamous cell

6. A 65 year old male presents to your GP surgery and complains of progressive dysphagia. He reports a 20 pack-year smoking history and previously owned a pub for 35 years. OGD performed and an oesophageal mass biopsy reveals intercellular bridges and high-keratin content. What is the diagnosis?

7. Worldwide, what is the most common type of oesophageal malignancy?

8. A 72 year old male presents to your GP surgery and complains of intermittent pain around the epigastrium. The patient looks slim with obviously loose clothing. He reports a 25 pack-year smoking history. He undergoes an OGD and a biopsy of the gastric body confirms: mitotic figures, invasion of the basement membrane and signet ring cells. What is the diagnosis?

9. The stomach mucosa is normally lined with which cell type?

10. A histopathologist describes a biopsy containing stratified squamous cells with mucous glands located in the submucosa. Which organ has the biopsy been taken from?